



## The heart and pericardium

The failing heart

---

---

---

---

---

---

### What will I gain from this video?

After watching this video, you will know how to identify the features of cardiac failure on a chest x-ray.

---

---

---

---

---

---

### Three stages

- Vascular redistribution
- Interstitial edema
- Alveolar edema

---

---

---

---

---

---

### Stage 1

- Vascular redistribution
- Interstitial edema
- Alveolar edema

---

---

---

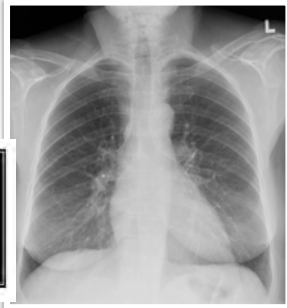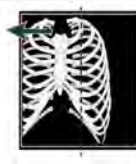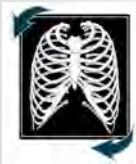---

---

---

### How to assess for vascular redistribution

STEP 1



---

---

---

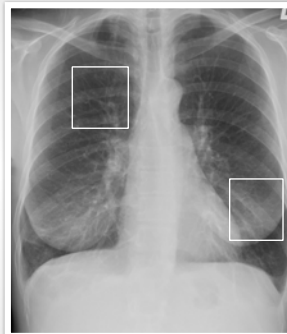
---

---

---

### How to assess for vascular redistribution

STEP 2



---

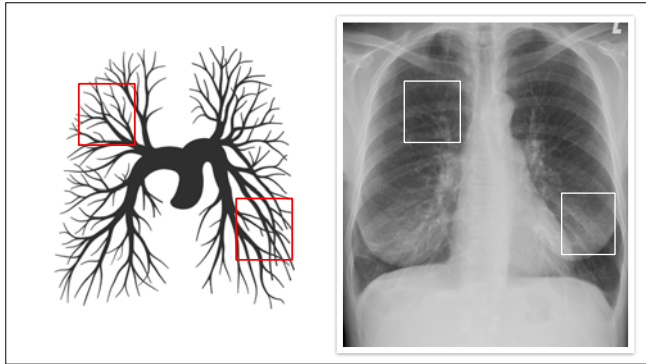
---

---

---

---

---



---

---

---

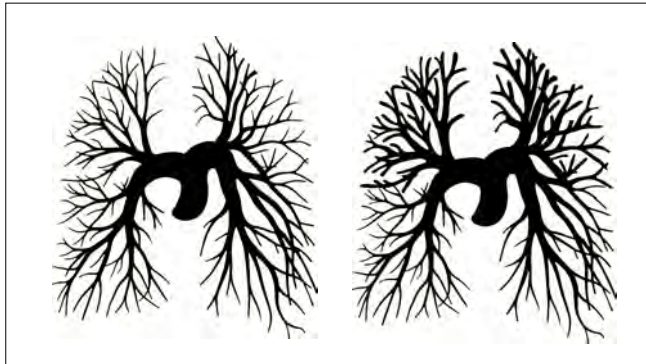
---

---

---

---

---



---

---

---

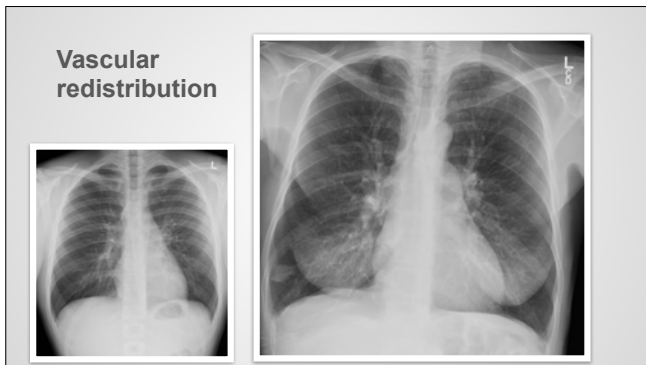---

---

---

---

---



---

---

---

---

---

---

---

---

**Stage 2**

- Vascular redistribution
- Interstitial edema
- Alveolar edema

---

---

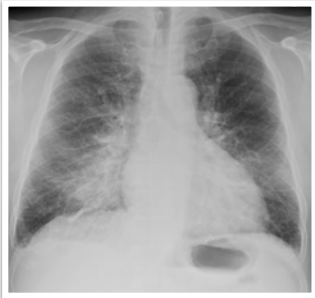
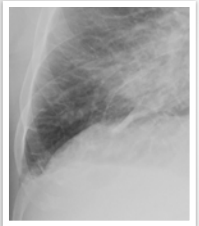---

---

---

---

**Interstitial edema**



---

---

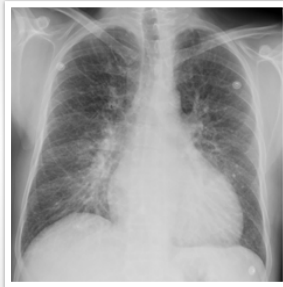
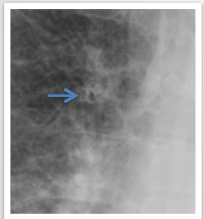
---

---

---

---

**Interstitial edema**



---

---

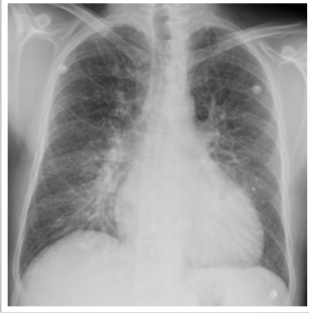
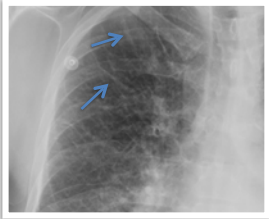
---

---

---

---

**Interstitial edema**



---

---

---

---

---

---

---

---

**Stage 3**

- Vascular redistribution
- Interstitial edema
- Alveolar edema

---

---

---

---

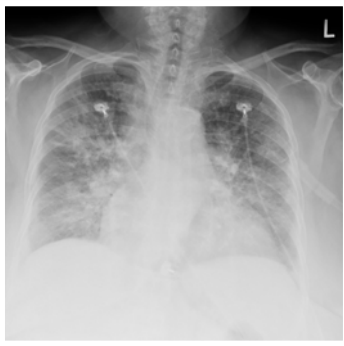---

---

---

---

**Alveolar edema**



---

---

---

---

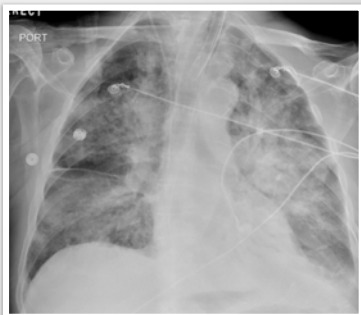---

---

---

---

Alveolar edema



---

---

---

---

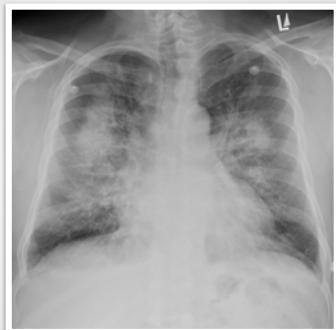
---

---

---

---

Case 1



---

---

---

---

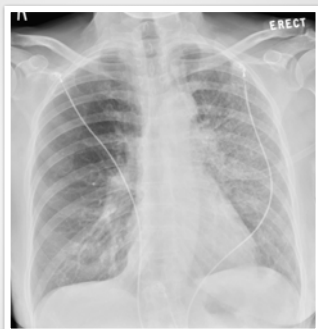---

---

---

---

Case 2



---

---

---

---

---

---

---

---

If suspecting cardiac failure look for...

- Vascular redistribution
- Interstitial edema
- Alveolar edema
- Cardiomegaly
- Pleural effusion

---

---

---

---

---

